



Haematological Effect of Ethanolic Leaves Extract of *Jatropha curcas* on *Plasmodium Berghei* Infected Mice

Ukpanukpong R.U.^{1*}, Bassey S.O.¹, Edoamodu C.E.², Ugor J.A.¹, Omang W.A.¹, Oduyiga, A.A.²

¹Department of Biochemistry, Faculty of Basic Medical Sciences, P.M.B 1115 University of Calabar, Cross River State, Nigeria

²Department of Biochemistry, College of Natural Sciences, P.M.B 5006 Joseph Ayo Babalola University, Ikeji -Arakeji Osun State, Nigeria

Abstract This study was aimed at investigating the haematological and histological effects of ethanolic leaves extract of *Jatropha curcas* on *Plasmodium berghei* infected mice. Forty eight mice weighing between 22-24g were assigned into six study groups of eight mice each. Forty mice were parasitized by *Plasmodium berghei* and used for extract and orthodox treated groups while eight mice were unparasitized. Group 1 was designated as positive control, group 2 was parasitized and designated as negative control. Group 3 was parasitized and designated as orthodox treated group of 100mg/kg body weight of Lonart DS. Group 4 to 6 were parasitized groups and treated with 400mg/kg, 100mg/kg and 200mg/kg body weight of ethanolic extract of *Jatropha curcas* leaves. Haematological parameters analyzed were hemoglobin (Hb), packed cell volume (PCV) and white blood cell (WBC). The hematological and histological investigations in groups 3, 4, 5 and 6 in orthodox and extract treated mice with 400mg/kg, 100mg/kg and 200mg/kg body weight of ethanolic extract of *Jatropha curcas* leaves showed significant reduction in their parasitemia levels compared to negative control group. The ameliorating effect of extract treated groups showed anti-plasmodia and anti-anemic activities which were confirmed in the histological tissues of *Plasmodium berghei* infected mice.

Keywords *Jatropha curcas*, *Plasmodium berghei*, Haematological indices, Histological tissues

Introduction

Malaria is a dangerous disease that is transmitted to humans by the bite of mosquitoes infected with *Plasmodium spp* [1]. World health organization reported that, about 3.4 billion people live in areas at risk of malaria transmission in 106 countries and territories. In 2013, it was reported that malaria caused 198 million clinical episodes and 500,000 deaths [2]. The parasite *Plasmodium* is the major cause of malaria infectious disease. Rollback malaria programme reported that malaria remained one of the major public problems in Sub-Sahara Africa [3]. Moreover, the people at risk of this infectious disease are children under the age of five years and pregnant women [4]. According to [5], over 729 per 100,000 children of less than five years of age in Nigeria die annually due to malaria infection; the disease is prevalent in tropical and sub-tropical regions and is a major obstacle to economic advancement of the regions leading to poverty and malnutrition. Malaria is one of the factors that lead to high maternal mortality rate in developing countries today. In pregnant women, malaria often results in anemia, spontaneous abortion, preterm babies with low-birth-weight and neonatal deaths among others. The intestine is not directly affected by malaria, although abdominal pains, fever and nausea are some of the associated symptoms of malaria. During *Plasmodium* infection in humans, capillaries of the intestinal villi may be blocked with parasitized erythrocytes [6] which leads to



gastrointestinal injury with attendant defects in metabolism [7]. The cellular constituents of the innate defense system in the intestine include epithelial cells, goblet cells, dendritic cells and macrophages. The front line of this system is the mucous layer containing goblet cells which secrete mucin [8].

Materials and Methods

Source of *Plasmodium Berghei*

The malaria parasite used was chloroquine sensitive strain of *Plasmodium berghei* (NK-65), obtained from Nigerian Institute of Medical Research, Yaba Lagos Nigeria and kept at the Department of Biochemistry, Joseph Ayo Babalola University, Ikeji-Arakeji, Nigeria. The parasite was maintained by serial blood passage in mice.

Animal treatment

Forty eight (48) mice were obtained from the Institute for Advanced Medical Research and Training, College of Medicine, University of Ibadan, Nigeria and used for the study. The animals had free access to food, tap water and were treated according to the international guidelines for the care and use of laboratory animals [9]. The animals were allowed for two weeks of acclimatization in the animal house, Department of Biochemistry, Joseph Ayo Babalola University.

***Plasmodium berghei* inoculation**

Animals were inoculated intraperitoneally with 0.2ml of infected blood suspension of parasitized erythrocytes on day zero. Parasitaemia was assessed by thin blood film collected from mouse tail and stained with Geimsia stain [10]. Parasitized mice of 5-7% were assigned to study groups II to VI of eight mice each.

Collection and identification of plant materials

Fresh leaves of *J. curcas* were harvested from Ikeji-Arakeji forest Osun State, Nigeria. The leaves were taken to the department of Botany, Obafemi Awolowo University (O.A.U) Ile-Ife for identification and authentication.

Preparation of plant extract

The leaves were washed and air dried at ambient temperature for days until well dried. The air dried leaves were pulverized into powder using laboratory blender and stored in an air tight container. One hundred grams of powdered sample were suspended in 600ml of 99.9% absolute ethanol contained in 1000ml beakers. The beakers were covered with foil paper to prevent evaporation and enhanced fermentation for 72hrs. The extract was filtered using Whatman No. 1 filter paper and the filtrate concentrated to dryness by evaporation over a steam bath at 80°C.

Experimental Design

Parasitized and non infected mice were assigned into 6 groups of 8 mice each as follows: group I: positive control, group II: parasitized mice and designated as negative control, group III: parasitized mice + Lonart DS (100 mg/kg b. wt), group IV: Parasitized mice + *J. curcas* (400 mg/kg b. wt), group V: Parasitized mice + *J. curcas* (100 mg/kg b. wt) and group VI: Parasitized mice + *J. curcas* (200 mg/kg b. wt)

Blood and tissue collection

At the expiration of treatment period, mice were starved overnight and sacrificed by decapitation. Blood and intestinal tissues were collected for biochemical and histological investigation. Blood sample collected was suspended in EDTA to prevent blood coagulation.

Heamatological indices

Haemaglobin level was determined by the method of [11] as modified by [12].

Estimation of percentage packed cell volume:

Values were read and converted from a micro-haematocrit reading device [13].

Estimation white blood cell count:

White blood cell count was computed using the method of [13].

Histological analysis

The method of [14] was used for histological analysis.



Statistics analysis

The data were statistically analyzed using one-way analysis of variance (ANOVA) and Duncan Multiple Range Test [15].

Results and Discussion

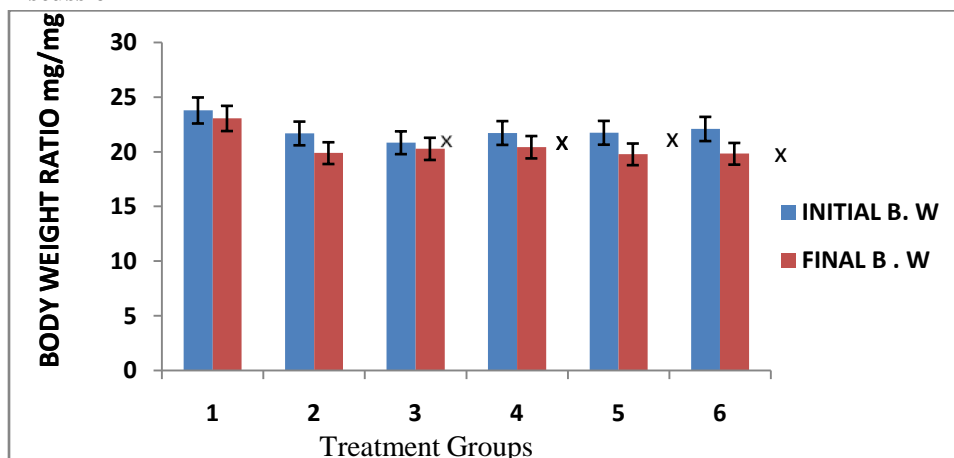


Figure 1: Body weights of control and *Plasmodium berghei* infected mice

The figure shows the effect of extract and orthodox drug on body weight indices of *Plasmodium berghei* infected mice. There was a significant reduction ($P < 0.05$) of final body weight of extract treated groups compared to positive control. A significant increase was observed in orthodox and extract treated groups 3 and 4 compared to the negative control group.

- 1 Positive control group
- 2 Negative control group
- 3 Lonart Ds treated group
- 4 Extract treated 400mg/kg group
- 5 Extract treated 100mg/kg group
- 6 Extract treated 200mg/kg group

X=Indicate significant difference compared to the control mice group (positive control).

Y=Indicate significant difference compared to malaria parasite group (negative control)

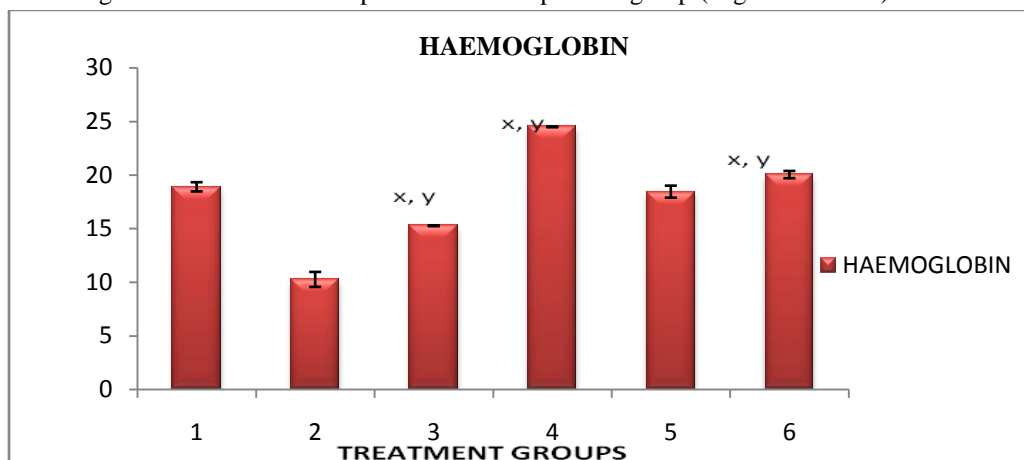


Figure 2: The Effect of *Jatropha curcas* extract on haemoglobin (g/dL) level of *Plasmodium berghei* infected mice.

The figure shows the untreated parasitized group 2 mice shows a significant decrease ($P < 0.05$) compared to the positive control group. Extract treated groups 4 and 6 show a significant increase ($P < 0.05$) compared to the positive and negative control groups.

- 1 Positive control group
- 2 Negative control group
- 3 Lonart Ds treated group
- 4 Extract treated 400mg/kg group
- 5 Extract treated 100mg/kg group
- 6 Extract treated 200mg/kg group

X= Indicate significant difference compared to the control mice group (positive control)

Y=Indicate significant difference compared to malaria parasite group (negative control).

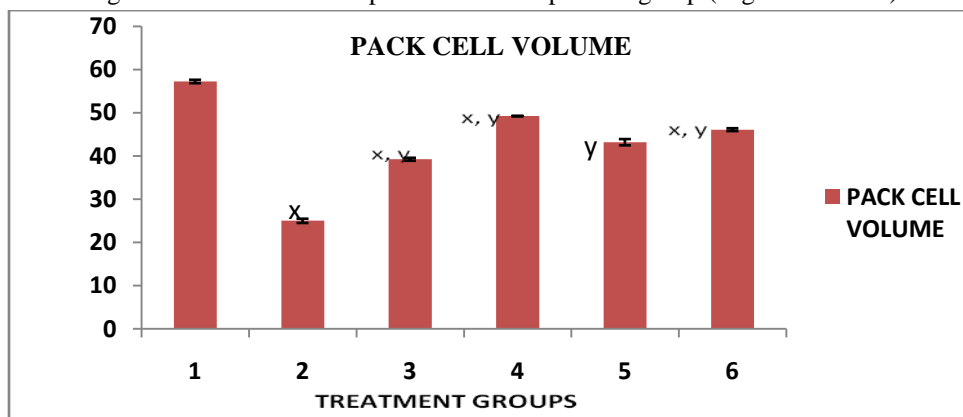


Figure 3: Effect of *Jatropha curcas* on Packed cell volume (%) level of *Plasmodium berghei* infected mice

The figure shows effect of extract and Lonart DS treated groups on packed cell volume of *Plasmodium berghei* infected mice. The untreated parasitized group 2 mice show significant ($P < 0.05$) decrease compared to the positive control group. Orthodox treated group showed significant decrease ($P < 0.05$) compared to groups 1 and 2. A significant increase ($P < 0.05$) was observed in extract treated groups 5 and 6 compared to the positive and negative control groups. The result shows that there is no significant difference in extract treated group 5 compared to positive control group.

- 1 Positive control group
- 2 Negative control group
- 3 Lonart Ds treated group
- 4 Extract treated 400mg/kg group
- 5 Extract treated 100mg/kg group
- 6 Extract treated 200mg/kg group

X=Indicate significant difference compared to the control mice group (positive control).

Y=Indicate significant difference compared to malaria parasite group (negative control).

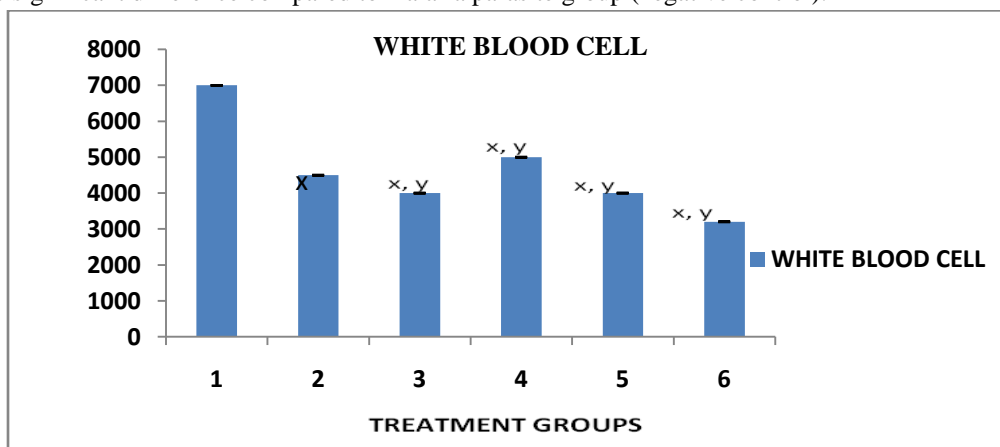


Figure 4: Effect of *Jatropha curcas* on white blood cell count of *Plasmodium berghei* infected mice



The figure shows effect of *Plasmodium berghei* infected mice in untreated, orthodox and extract treated groups. The untreated parasitized group 2 showed significant decrease ($P < 0.05$) compared to the positive control group. A significant increase was observed in extract treated group 4 compared to the positive control group. Orthodox and extract treated groups 3, 5 and 6 showed significant decrease ($P < 0.05$) compared to positive and negative groups.

- 1 Positive control group
- 2 Negative control group
- 3 Lonart Ds treated group
- 4 Extract treated 400mg/kg group
- 5 Extract treated 100mg/kg group
- 6 Extract treated 200mg/kg group

. X= Indicate significant difference when compared to the control mice group (positive control)

Y=Indicate significant difference when compared to malaria parasite group (negative control).

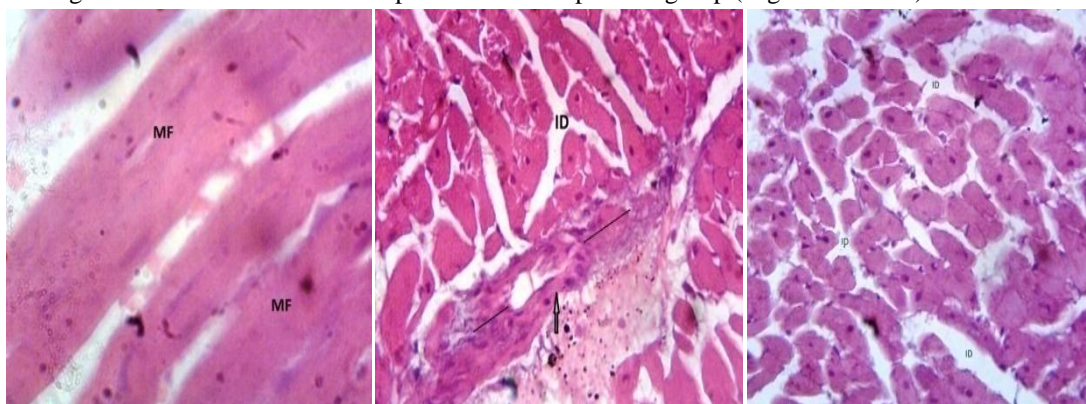


Plate 1-3: Shows effect of *Jatropha curcas* extract and Lonart DS on intestinal tissues of *Plasmodium berghei* infected mice

Plate 1 shows normal intestine with no inflammation. Plate 2 shows heavily inflamed intestine compared to positive control group. Plate 3 *Plasmodium berghei* treated Lonart DS group shows intestinal distention.

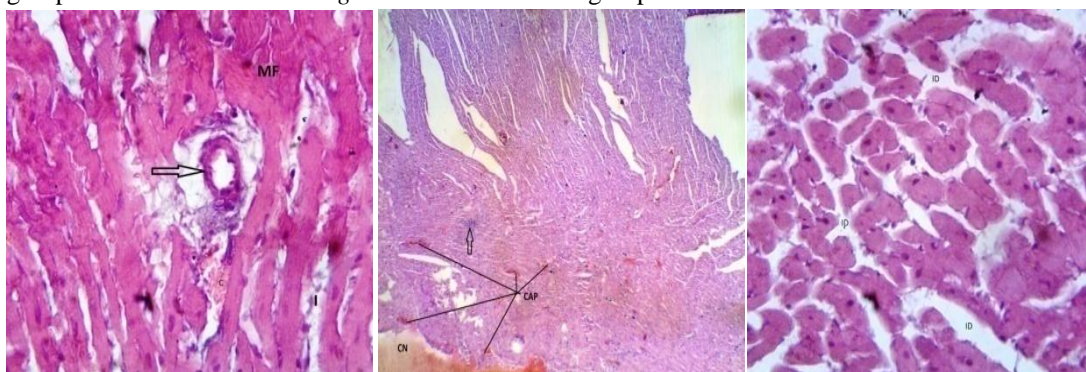


Plate 4-6: Shows effect of *Jatropha curcas* extract on intestinal tissues of *Plasmodium berghei* infected mice

Plate 4 shows mild congestion and less free inflammation of intestinal cell. Plate 5 shows foci (the first sign of tumor or disease) in the intestine which may occur as a result of inflammation and plate 6 shows intestinal distention.

Discussion

Haematological indices were considered in this study because the most pronounced changes related to malaria involve the blood and the blood forming system. Anaemia is a fairly common problem encountered in malaria [16]. This is evidenced by the decrease in PCV, WBC and Hb in all the infected animal groups. Haemolysis which is the destruction of red blood cells of parasitized mice may be due to high parasitemia in the red blood cell that causes

changes of red cell antigen structure brought about by the parasitic invasion which stimulates the mice production of antibodies against the red cell. This triggers immune mediated red cell lyses. In addition, the growing parasite consumes and degrades the intracellular proteins which are mainly hemoglobin [17]. This may account for further reduction in Hemoglobin. These reductions were considerably reversed in the infected mice treated with 400mg/kg and 200mg/kg body weight of extract but Lonart DS treated group shows no significant increase. This suggests that the extract may enhance the production of red blood cells (erythropoiesis). This might have contributed to the increase in PCV and Hb observed in extract treated groups. Decrease in WBC of untreated infected group (Negative control) was observed which leaves the mice at great risk of having infection. The observed increase in WBC in the infected mice group treated with 400mg/kg body weight of extract may result from stimulation of the immune system of the mice to fight malaria parasites. White blood cells function mainly to fight infection, defend the body by phagocytosis against invasion of pathogenic organisms, produce and distribute antibodies in the immune response. Also a decrease in WBC was observed in groups 5 (100mg/kg) and 6 (200mg/kg) of extract treated mice. This may be due to reduction in the ability of the mice to resist the infection [18]. An increase was observed in WBC mice of group 4 (400mg/kg) extract treated mice which suggests a boost in the immune system by the extract [16]. The decrease may be as a result of WBC fighting the infection bringing about the reduction. Packed cell volume (PCV) which is a measure of the relative mass of cells present in the blood was observed to increase in all the groups that were treated as observed on the day that the animals were sacrificed. A decrease was observed in infected but untreated group 2 and in Lonart DS treated group 3 which signify the possible presence of anaemia state [19]. Anaemia is a condition characterized by decrease in total cell mass of the blood. The intestine comprises small and large parts. Small intestine is the part of the gastrointestinal tract between the stomach and the large intestine, and is where most of the digestion and absorption of food takes place. The primary function of the small intestine is the absorption of nutrients and minerals from food [20]. Malaria and intestinal parasitic infections are distributed throughout the world and are highly prevalent in humid and warm environments in the tropics [21]. A highly parasitized mouse develops co-infection (anaemia, diarrhea, inflammatory cell etc); plasmodium infections affect the intestine at the immunological level when the immune system is low [22]. This study has shown that *Jatropha curcus* may ameliorate the infection caused by mosquito parasites and the damage caused to the intestine.

Conclusion

Findings in this research showed that 200mg/kg and 400mg/kg body weight of extract treated groups might have anti-plasmodial and anti-inflammatory potentials. Moreover, stringent measures should be observed to guide against overdose which is a common challenge with herbal medicine.

References

1. Mehlhorn, H. (2014). Encyclopedic reference of parasitology. 4th Edn. Berlin Springer. 1, 939-945.
2. Harvey, V., & Fineberg, M.D. (2014). Pandemic preparation and response of malaria. *N. Eng. J. Med.*, 370, 1335-1342.
3. Tripathi, K.D. (2013). Essentials of medical pharmacology. 7th Edition, Jaypee Brothers Medical Publishers (P) Ltd. New Delhi, 816-883.
4. Uraku, A.J., Okaka, A.N.C., Ibiam, U.A., Agbafor, K.N., Obasi, N.A., Ibiam, P.M., Obasi, O.U., & Nwalo, F.N. (2015). Antiplasmodial Activity of Ethanolic Leaf Extracts of *Spilanthes uliginosa*, *Ocimum basilicum* (Sweet Basil), *Hyptis Spicigera* and *Cymbopogon citratus* on Mice Exposed to *Plasmodium berghei* Nk 65. *International J. of Biochem. Research and Review*, 6(1), 28-36.
5. Ugwu, P.C., Nwodo, F.C., Joshua, P.E., Odo, E.C., Bawa, A., Ossai, C., & Adonu, C. (2013). Anti-malaria and Hematological Analyses of Ethanol *Moringa oleifera* Leaf on Malaria Infected. *International Journal of Pharmacy and Biological Sciences*, 3(1), 360-371.
6. Seydel, K.B., Milner, D.A., Kamiza, S.B., Molyneux, M.E., & Taylor, T.E. (2006). The distribution and intensity of parasite sequestration in comatose Malawian children. *J. Infect Dis*, 194, 208-215.



7. Wilairatana, P., Meddings, J.B., Ho, M., Vannaphan, S., & Looareesuwan, S. (1997). Increased gastrointestinal permeability in patients with *Plasmodium falciparum* malaria. *Clin Infect Dis*, 24, 430-435.
8. Corfield, A.P., Myerscough, N., Longman, R., Sylvester, P., Arul, S., Pignatelli, M., & Mucins M. (2000). Mucosal protection in the gastrointestinal tract: New prospects for mucins in the pathology of gastrointestinal disease. *Gut*, 47, 589-594.
9. National Institutes of Health (1985). Guide for the Care and Use of Laboratory Animals. 14, 89-544.
10. World Health Organization, (2000). Severe Falciparum malaria. *Trans. R. Soc. Trop. Med. Hygs*, 94, 1-290.
11. Crosby, W.H., Munn, J.I., & Furth FW. (1954). Standardizing methods for clinical hemoglobinometry. *US Armed Forces Med. J.*, (5):693-703.
12. Pla, G.W., & Fritz, J.C. (1971). Collaborative test in chicks and rats for measuring availability of Iron. *Journal of Association of Analytical Chemist.*, 54(1), 13-17.
13. Dacies, J.V., Lewis, S.M. (1975). Practical hematology. 5th (ed) Edinburge: Church Hill Livingstone. 541-675.
14. Drury, R.A., & Wallington, E.A. (1980). Histological techniques, 5th edition, London Oxford University Press, London, 199-220.
15. Mahajan, B.K. (1997). Significance of difference in mean. In: Methods in Biostatistics for medical and research workers. 6th edition. JAYPEE Brothers Medical Publishers, New Delhi, 130-155.
16. Balogun, E.A., Adebayo, J.O., Zailani, A.H., Kolawole, O.M., & Ademowo, O.G. (2009). Activity of ethanolic extract of *Clerodendrum violaceum* leaves against *Plasmodium berghei*. *Agric. Biol. J.N. Am.* 1(3), 307-312.
17. Gavigan, C.S., Dalton, J.P., & Bell, A. (2001). The role of aminopeptidases in haemoglobin degradation in *Plasmodium falciparum* infected erythrocytes. *Mol. Biochem. Parasitol.*, 117(1), 37-48.
18. Yakubu, M.T., Akanji, M.A., Oladiji, A.T. (2007). Hematological evaluation in male albino rats following chronic administration of aqueous extract of *Fadogia agrestis* stem. *Phcog. Mag*, 3(9), 34-38.
19. Adam, I., Khamis, A.H., & Elbashir, I.M. (2005). Prevalence and risk factors for *Plasmodium falciparum* malaria in pregnant women of eastern Sudan. *Mal. J.*, 4, 18-23.
20. Drake, R.L., Vogl, W., Tibbitts, A.W., & Mitchell, M. (2005). Illustrations by Richard; Richardson, Paul (2005). Gray's Anatomy for students. Philadelphia: Elsevier/Churchill Livingstone. 295-299.
21. World Health Organization, (1998). Insecticides Susceptibility. 98, 12.
22. Wang, M.L., Cao, Y.M., Luo, E.J., Zhang, Y., Guo, Y.Y.J. (2013). Pre-existing *Schistosoma japonicum* infection alters the immune response to *Plasmodium berghei* infection in C57BL/6 mice. *J. Malar. Pub.Med Central* 12, 322.

