



Histological Effects of *Anastatica hierochuntica* Aqueous Extract in Female Mice Livers

Asal A. Tawfeeq

Medical Laboratory Techniques Department/Technical College / Northern Technical University, Iraq

Abstract The plant *Anastatica hierochuntica* is widely used for the treatment of difficult childbirth, gastrointestinal disorders and many other medical conditions. Therefore, this study was designed to evaluate the histological effects of *Anastatica hierochuntica* in mice female liver tissues where total of (30) mice females at the ages of (4-8 weeks) and body weight of about (25 ± 2 g) were divided into three groups. The first group was the control group which received daily oral administration of (1ml) of distilled water for two months. The second group (plant-treated group1) was orally administered with a daily dose of (0.1g/ml) of the *Anastatica hierochuntica* aqueous extract for one month. While, the third group (plant-treated group 2) received the same dose to the second group but for two months only. Animals were killed at the end of the first and the second month with consideration of the control group and livers were autopsied and their liver slide sections were examined by light microscope and photographed. Then, images were assessed histologically and comparisons were made between the treated groups of mice and the control group.

Results showed that, the administration of daily oral doses of (0.1g/ml) of *Anastatica hierochuntica* aqueous extract for more than one month produced significant changes ($P \leq 0.05$) on mice females liver tissues that included lymphocyte infiltration, necrosis, liver tissue fatty degeneration and congestion and dilatation of the hepatic vein.

In a conclusion, the prolonged use of the aqueous extract of the plant for more than one month is associated with significant side effects on mice liver.

Keywords Histological effects, *Anastatica hierochuntica*, aqueous extract, mice livers.

Introduction

Herbal medicines were used by about 80% of the world's population, primarily in developing countries for routine health care, and also enter the therapeutics in the developed countries [1]. These herbs escape toxicity testing before they are marketed as traditional medicines due to inadequate drug laws. Yet many reports reveal that drugs of plant origin are not free from toxic effects [2-4]. *Anastatica hierochuntica* belongs to the family Crucifera and the only member of the genus *Anastatica* [2]. It is a small, gray winter annual herb that grows to a maximum height of 15 cm, and produces small white flowers and it is found in the arid regions of Saudi Arabia, Egypt, Jordan, Iraq, the UAE, Iran, Kuwait, and North Africa, and can survive without water for long periods [3]. The whole plant contains flavonoids, luteolin-7- glucoside, isovitexin, kaempferol 7-glucoside, kaempferol 3-rhamnoglucoside, quercetin and lucitin. It also contains glucosinolates: glucoiberin and glucocheirolin. The fruits contain glucose, galactose, fructose, sucrose, raffinose and stachyose [1-2].

In Arab countries *Anastatica hierochuntica*, is known as Kaff Maryam, where it is widely consumed as a tea beverage. It is powdered, mixed with honey and taken for the treatment of many conditions, in particular as a remedy for difficult childbirth and uterine hemorrhage [4-5]. In addition, it is used to treat asthma, gastrointestinal disorders, depression, high blood pressure, indigestion, headache, cold, fever, malaria, epilepsy, fatigue, diabetes, heart disease, and infertility [4-6]. However, many these studies had identified and quantified a number of minerals and phenolic compounds from this plant used for treating health disorders. But fewer studies were available on the histological effect of the prolonged use of *Anastatica hierochuntica* on different body organs [3].

Therefore, this study was aimed to evaluate the histological effects of *Anastatica hierochuntica* plant aqueous



extract in mice female liver tissues.

Materials and Methods

Animals Management

Healthy, adult mice female animals of *Mus musculus* strain were used in this study, ranging in age between 4-8 weeks old and their weight were about (25 ± 2 g). Animals were divided into three equal groups (each group consisted of 10 females) and were kept in an air condition room at a temperature of (22-24 °C) with about (12-14) hours of day light exposure. Animals were housed in cages measuring (29*15*12 cm) and each seven animals were kept in one cage contained wooden shave. Water and Feed composed of (wheat, barely mixed with 250 mg of milk powder) were freely excess able and animals were kept for at least two weeks for adaptation. Animal cages were cleaned and sterilized with 70% ethanol once a week regularly according to standard procedure [7].

1. Plant used in the study:

Samples of whole dried *Anastatica hierochuntica* plant were brought from Kingdom of Saudi Arabia. The aerial parts of the plant were isolated and kept in airtight glass containers till the time of the experiments.

2. Treatment:

The dried plant was ground to fine powder and about (1g) of the powder was mixed with (10ml) of distilled water and were incubated for 3hrs at (60) °C. Suspension was then filtered with filter paper (Wattman No.1) and the water extracts were prepared fresh daily just before administration orally to the experimental animals in a dose of (1ml/mouse of 25 g) according to standard procedure [8].

3. Experimental protocol:

Experimental animals were divided into three groups (10 mice each):

The control group mice were orally administered with a daily dose of (1ml) distilled water for 2 months.

1. Plant –treated group1 were orally administered with a daily dose of (0.1g/ml) of the *Anastatica hierochuntica* water extract for one month.
2. Plant –treated group2 were orally administered with a daily dose of (0.1g/ml) of the *Anastatica hierochuntica* water extract for two months.

Two animals from both the control and the plant - treated group 1 were killed after one week of the treatment and their liver tissues were assessed histological. Then, the rest of the animals of the Plant –treated groups 1 and 2 were killed after one and two months for liver tissue histological assessment with regard to the control group.

4. Histological assessment:

Animals were autopsied and liver tissues were excised, fixed in 10% formalin and were embedded in paraffin. Tissue sections were cut at 5µm, mounted on slides, stained with hematoxylin- eosin (H-E) for general livers structure examination. The sections were examined by light microscope (Optika- Italy) and photographed by (Optica- Italy 4083-B5- camera) according to standard procedures [9-10].

5. Statistical analysis:

Data from the study were analyzed using T- test by using SPSS program Ver.10 for Windows. *P* value of $p \leq 0.05$ was considered indicative of a statistically significant difference.

Results & Discussion

Many studies had identified and quantified a number of minerals and phenolic compounds extracted from the plant *Anastatica hierochuntica* used for the treatment of many health disorders [1-3]. Moreover, this plant have been traditionally used by pregnant women to treat pregnancy related illnesses, thus encouraging a healthy pregnancy and postpartum well-being depending on a single or few doses of the plant extract [11]. However, there are very limited studies are available on the side effects and safety of the prolonged use of the plant on different body organs especially pregnant women and children [11-13].

On the other hand, Liver is the most important organ, which play a pivotal role in regulating various physiological processes in the body and is involved in several vital functions, such as metabolism, secretion in addition to the great capacity in the detoxification of many toxic substances. Therefore, damage to the liver inflicted by hepatotoxic agents is of grave consequences [14]. Thus, this study was implicated in order to evaluate the effect of the continued use of the aqueous extract of the plant *Anastatica hierochuntica* on mice female livers and table (1) showed results of the macroscopic examination of the biopsied liver tissues from the three animal groups.

Results of table (2) had shown that, there were no significant macroscopic changes noted in the control untreated mice and their livers appeared normal in shape and size. Whereas, the continued treatment of animals with (120g/ Kg) of the aqueous extract of the plant *Anastatica hierochuntica* for one and two months respectively resulted in the congestion and enlargement of the livers of the treated animals. On the other hand, the histological findings of



this study showed that, a single dose of (0.1g/ml) for one day of the aqueous extract of the plant *Anastatica hierochuntica* produced no liver lesions and livers of the plant – treated mice females appeared as normal as the control (Group 1) livers (Figure-1a&1b). This result came in agreement with the results obtained in [5,13] where they declared that, the administration of fewer, low doses of extracts from the plant *Anastatica hierochuntica* associated with no side effects. Yet, they affirmed on the hepato-protective effect of the plant where, the (anastatins A and B flavonoids) isolated from the methanolic extract of the *Anastatica hierochuntica* were found to show hepato-protective effects [13].

Table 1: Macroscopic changes observed in the livers of mice treated with different concentrations of *Anastatica hierochuntica* aqueous extract.

Animal Groups	<i>Anastatica hierochuntica</i> Concentration/Kg	Macroscopic changes in mice females livers
*Group 1	0 mg/kg	Normal
Group 2	120g/Kg	Congested
Group 3	240g/Kg	Enlarged

*Group 1= Control group, Group 2= Plant-treated female mice for one month, Group 3 =Plant-treated female mice for two months.

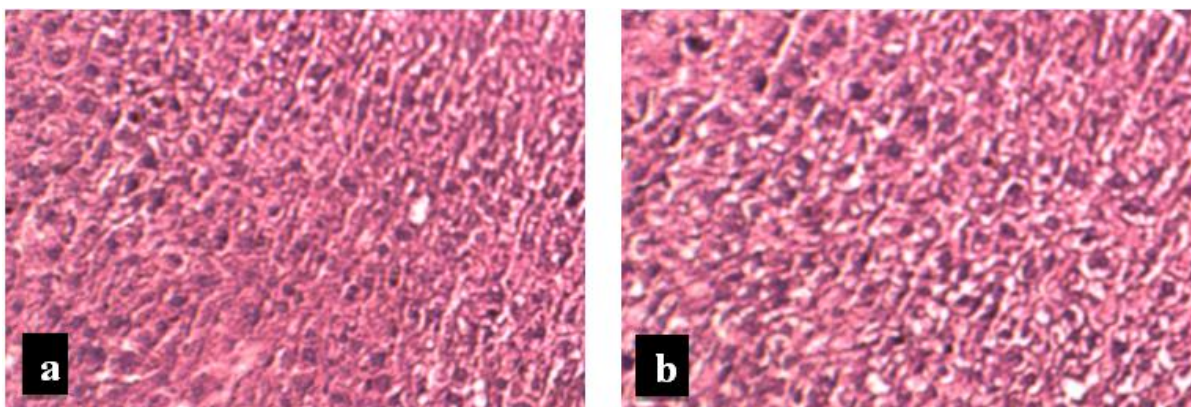


Figure 1: Histological sections of mouse liver showing;
a- Liver section of normal control mouse at (10X), b- Hepatocyte of liver section of Group 2 at (40X), (H & E staining).

Histological examination of female mice liver tissues treated with a single dose of (0.1g/ml) for one day of the aqueous extract of the plant *Anastatica hierochuntica* showed normal liver histology (Figure-1b) with radial hepatic cord and clear hepatic sinusoid. Yet, the histological examination of livers tissues excised from female mice treated with (0.1g/ml) of the aqueous extract of the plant *Anastatica hierochuntica* for one month (group 2) showed a significant increase ($P \leq 0.05$) in the histological changes ranged from mild to severe as shown in table (2).

Table 2: Percentage of the histological liver changes scored among mice groups treated with different concentrations of the aqueous extract of the plant *Anastatica hierochuntica*.

Groups of Mice	<i>Anastatica hierochuntica</i> Concentration/Kg	The percentage of histological changes in livers				
		LI%	N%	FD%	CDCV%	C&D%
Control	0mg/Kg	0%	0%	0%	0%	0%
Group 2	120g/kg	71%	52%	0%	15%	10%

*LI= Lymphocyte Infiltration, N=Necrosis, FD= Fatty Degeneration, CDCV= Congestion and dilatation of the central hepatic vein and C&D= Congestion and Dilatation.

Results of table (2) revealed that, the liver tissue sections of the control group (Group1) showed no histological changes. While, liver tissue sections biopsied from female males treated with a total concentration of (120g/Kg) for one month presented many histological changes ranged from mild to severe where (71%) of the autopsied female mice showed inflammatory cellular infiltration mainly lymphocytes and neutrophils. While, (52%) of them showed necrosis in their liver tissue sections. Yet, about (15%) of Group2 animals showed congestion and dilatation of central hepatic vein, whereas, only (10%) of the liver tissue sections showed congestion. While, no fatty degeneration was detected in the tissue sections being examined.



Thus, treatment of female mice with daily oral doses of (0.1g/ml) for one day of the aqueous extract of the plant *Anastatica hierochuntica* produced many histological changes in the liver tissue sections shown in (Figure-2) which included; chronic inflammatory cells mainly lymphocytes and neutrophils indicative of necrosis. In addition, some hepatocytes showed dense nucleuses suggestive of necrosis in addition to the vacoulation and congestion.

These results however, did not agree with the results obtained in [5,13,15] where they stated hepato-protective and anti-hepatotoxicity effects in mice liver tissue sections treated with different extracts of the plant *Anastatica hierochuntica* for two to three weeks. Though, animals of Group2 were treated for one month and received (120g/Kg) of the plant *Anastatica hierochuntica* which might explain the histological changes detected.

Moreover, mice were further treated for a second month in order to evaluate the effect of prolonged use of the aqueous extract of the plant on liver tissue sections and results were shown in (Figure-3) that showed a significant increase ($P \leq 0.05$) in lymphocyte infiltration and necrosis, congestion, congestion and dilatation of the central hepatic vein in addition to the recognition of fatty degeneration and the enlargement in the hepatic Kupffer cells in the liver tissue sections of Group3 animals.

Moreover, the degenerative lesions were more severe in most of the animals and about (22%) of the examined liver tissue sections showed sever liver injury and a complete loss of architecture.

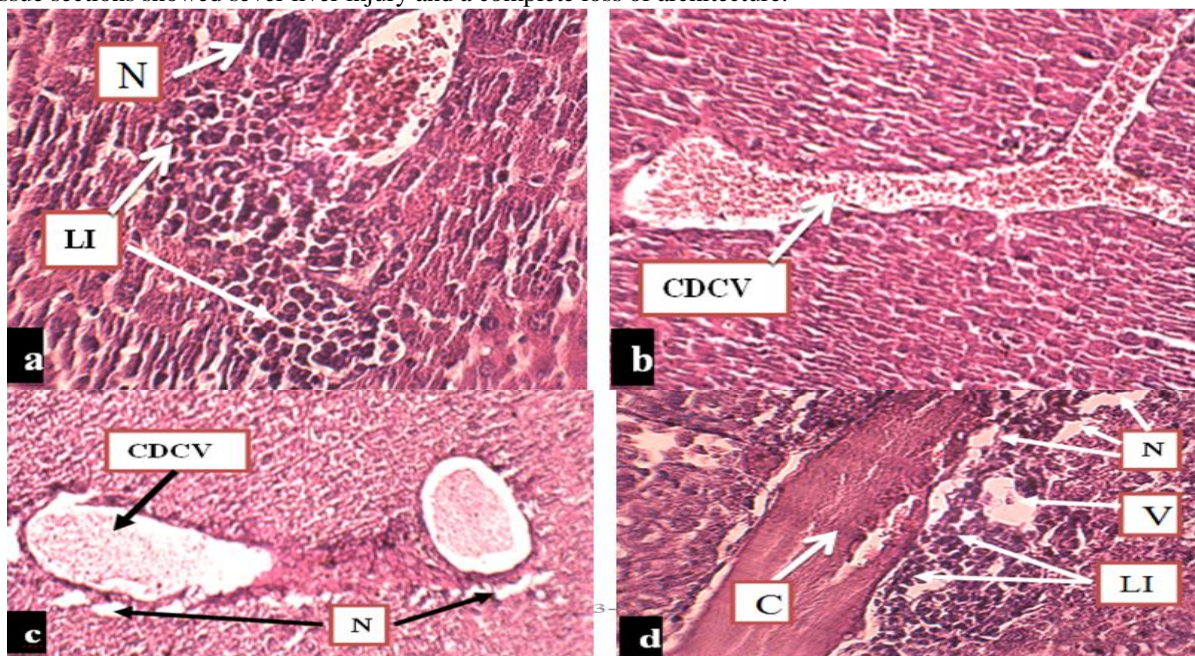
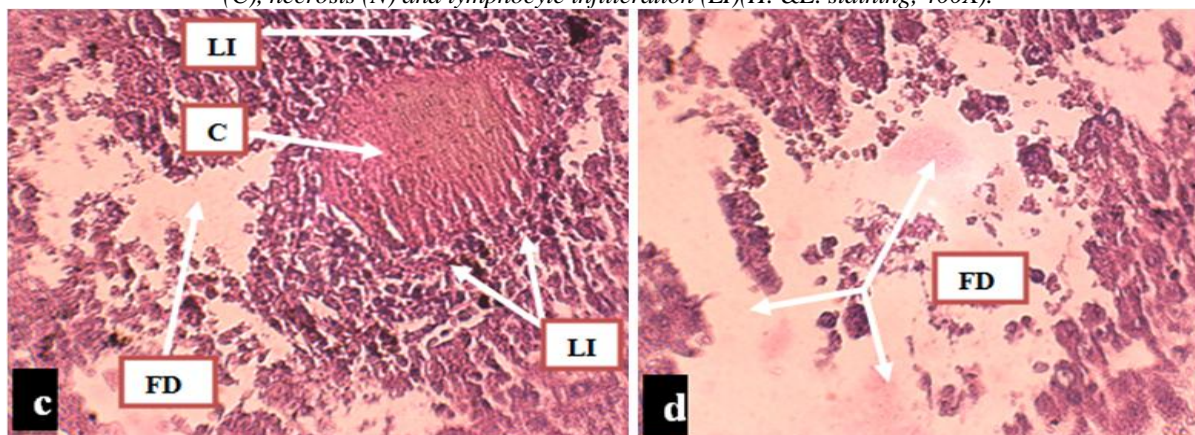


Figure 2 :Liver section of female mice-Group2 treated with (0.1g/ml) of aqueous extract of *Anastatica hierochuntica* for one month showing: a- Cellular necrosis (N) and lymphocyte infiltration (LI), b- Congestion and dilatation of hepatic vein (CDCV), c= Congestion and dalitation of hepatic vein (CDCV), N=Necrosis and d = Vacoulation (V), congestion (C), necrosis (N) and lymphocyte infiltration (LI) (H. &E. staining, 400X).



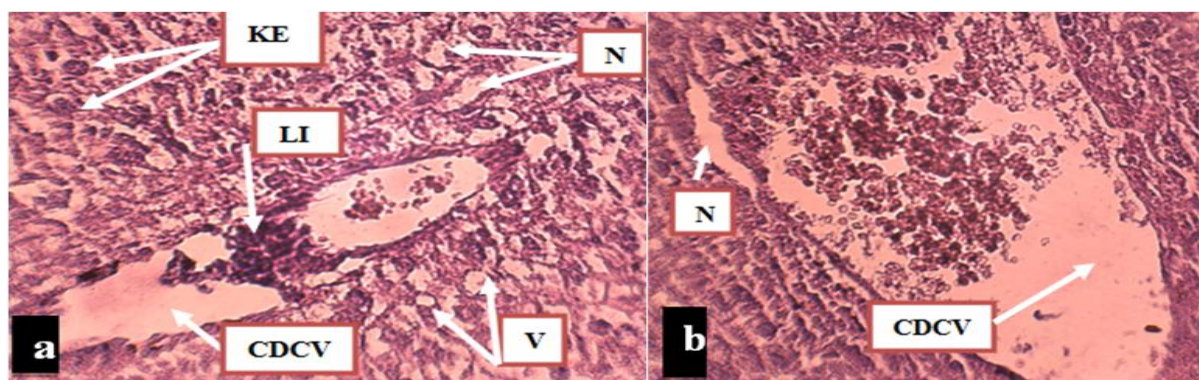


Figure 3: Liver sections of female mice-Group3 treated with (0.1g/ml) of aqueous extract of *Anastatica hierochuntica* for two months (H. &E. staining, 40X) showing; Necrosis (N) and lymphocyte infiltration(LI),Enlargement of Kupffer cells(KE).Congestion and dilatation of hepatic vein(CDCV) with Vacuolation (V).Congestion (C), Fatty Degeneration(FD) and lymphocyte infiltration(LI).Fatty Degeneration (FD) and the complete loss of hepatic architecture.

However, the histological effects of the administration of the aqueous extracts of the plant *Anastatica hierochuntica* for two months were more elucidated in table (3).

Table 3: Percentage of the histological liver changes scored among mice groups treated with different concentrations of the aqueous extract of the plant *Anastatica hierochuntica*

Groups of Mice	<i>Anastatica hierochuntica</i> Concentration/Kg	The percentage of histological changes in livers					
		LI %	N %	FD %	CDCV %	C %	KE%
Control	0mg/Kg	0%	0%	0%	0%	0%	
Group 3	240g/kg	94%	82%	81%	66%	89%	37%

*LI= Lymphocyte Infiltration, N=Necrosis, FD= Fatty Degeneration, CDCV= Congestion and dilatation of the central hepatic vein and C= Congestion, V= Vacuolation and KE=Kupffer cells enlargement.

As provoked by the results in the table above, an elevation in the degenerative lesions that resulted in a significant hepatic damage was associated with the continual of the daily oral administration of (0.1g/ml) for one day of the aqueous extract of the plant *Anastatica hierochuntica* for two months. Consistent with these findings were the observations of [16-18] where they declared that, the plant *Anastatica hierochuntica* contain a combination of silica, zinc, iron and aluminum minerals. Consequently, the sever hepatotoxicity noticed after the prolonged administration of the aqueous extract of the plant might be probably due to the accumulation of high concentration of these minerals in the vital organs over long periods of time of plant extract administration. The possible effect of mineral accumulation is shown in table (4).

Table 4: Toxic effect of the minerals found in the aqueous extract of the plant *Anastatica hierochuntica* mentioned by other studies with their references.

Minerals	Toxic Effect on liver	References
Iron	Iron-induced free radical reactions and oxidative injury	[19-20]
Silica	Microgranulation in the liver	[21-22]
Zinc	Extensive vacuolation with sever necrosis	[20]
Aluminum	Congestion of the central hepatic vein	[20]

Subsequently, adverse reactions were also been reported in some clinical trials where a review of 30 studies involving 11506 subjects reported a total of 246 adverse events, thus representing an adverse reaction rate of approximately 2% [23]. The major reactions reported included acne, changes to the menstrual cycle, dizziness, gastrointestinal distress, increased menstrual flow, nausea, skin reactions, urticaria and weight gain [24]. Minor adverse events include fatigue, hair loss, increased intraocular pressure, palpitations, polyurea, sweating and vaginitis [25].

Yet, Estrogen-dependent breast cancer patients should use the plant *Anastatica hierochuntica* preparations with caution, as weak estrogenic effects have been reported *in vitro* [8,12].

Conclusions

1. In specific, a single oral dose of (0.1g/ml) of the aqueous extract of the plant *Anastatica hierochuntica* had no detectable effect on mice liver histology.



2. Prolonged use of the aqueous extract of the plant for more than one month is associated with significant side effects included cellular infiltration and lesions of necrotic hepatocytes with congestion and dilatation of hepatic vein.
3. Liver is a vital organ in the body. Thus, the administration of any herb for the treatment of any medical conditions should be considered carefully to avoid liver damage of the patient.

Treatment of women especially the pregnant ones with the aqueous extract of the plant *Anastatica hierochuntica* should be taken seriously due to the hepatic side effects of this extract on their liver to avoid complications.

Treatment of women especially the pregnant ones with the aqueous extract of the plant *Anastatica hierochuntica* should be taken seriously due to the hepatic side effects of this extract on their liver to avoid complications.

References

1. Noura, A., William, M. and Alan, C. Tea prepared from *Anastatica hierochuntica* seeds contains a diversity of antioxidant flavonoids, chlorogenic acids and phenolic compounds. *Phytochemistry*, 2011, 72:248-254.
2. Kamboj, V. P. Herbal Medicine. *Curr. Sci.*, 2000, 78:35-37.
3. Ihsanullah, D. Chemical properties of the medicinal herb Kaff Maryam (*Anastatica hierochuntica* L.) and its relation to folk medicine use. *African Journal of Microbiology Research*, 2012, 6(23): 5048-5051.
4. El-Ghazali G.E., Al-Khalifa K.S., Saleem G.A., Abdallah E.M. Traditional medicinal plants indigenous to Al-Rass province. *Saudi Arabia. J. Med. Plant Res.*, 2010, 4: 2680-2683.
5. Eman A.S., Tailang M., Benyounes S., Gauthaman K. Antimalarial and hepatoprotective effects of entire plants of *Anastatica hierochuntica*. *Int. J. Res. Phytoch. Pharm.*, 2011, 1: 24-27.
6. Batanouny K.H. *Wild Medicinal Plants in Egypt*. The Palm Press. Cairo, 1999, 207.
7. Tawfeeq, A.A. Developmental effects of 5-azacytidine and folic acid in Mice. Ph.D. thesis, AL-Nahrain University, Baghdad, Iraq, 2005, 54.
8. Baker, R.K., Mohammad, T.U., Ali, B.H. and Jmameel, N.M., The Effect of Aqueous Extract Of *Anastatica Hierochuntica* On Some Hormones In Mouse Females. *Ibn Al-Haitham Jour. for Pure & Appl. Sci*, 2013, 26(2):198-203.
9. Chelab, K.G. and Majeed, S.Kh. Methotrexate-induced histopathological changes in the kidneys of mice. *Iraqi Journal of Veterinary Sciences*, 2009, 23(2):219-222.
10. Luna, L.G. Manual of Histologic staining methods of the armed forces. Institute of Pathology. 3rd Ed., McGraw-Hill Book Company, N. Y., Toronto, London, Sydney, 1968, 12-31.
11. Law, K.S., Soon, L.K., Syed Moshin, S.S.J. and Farid, C.G. Ultrastructural Findings of *Anastatica hierochuntica* L (Sanggul Fatimah) towards explaining its Medicinal Properties. *Annals of Microscopy*, 2009, 9: 50-56.
12. Tiran, D. The use of herbs by pregnant and childbearing women: a risk-benefit assessment. *Complementary Therapies in Nursing and Midwifery*, 2003, 9: 176-181.
13. Masayuki, Y., Fengming, Xu., Toshio, M., Kiyofumi, N. and Hisashi, M. Anastatine A and B, New Skeletal Flavonoids with Hepatoprotective Activities from the Desert plant *Anastatica hierochuntica*. *Bioorganic & Medicinal chemistry Letters*, 2003, 13: 10451049.
14. Rathi, M.A., Thirumoorthi, L., Sunitha, M., Meenakshi, P., Gurukumar, D. and Gopala krishnan, V.K. Hepatoprotective activity of spermacocehisipida against nitrobenzene induced hepatotoxicity in rats. *Journal of Herbal Medicine and Toxicology*, 2010, 4(2): 201-205.
15. Al-Azzawie, H.F. Anti-Hepatotoxic Effect of the Methanolic *Anastatica hierochuntica* Extract In CCl₄⁻ Treated Rats. *Eng. & Tech. Journal*, 2011, 29(2): 413-423.
16. Hassan, F. and Shaaban, J. Use of traditional/complimentary medicine among adult patients attending Family Medicine Clinic at Hospital University Sains Malaysia. *International Medical Journal*, 2005, 12:1-6.
17. Nordeng H. and Havnen, C. Impact of socio-demographic factors, knowledge and attitude on the use of herbal drugs in pregnancy. *Acta Obstet Gyneco Scandl*, 2005, 84: 26-33.
18. Guerrero, M.P., Volpe, S.L. and Mao, J.J. Therapeutic uses of magnesium. *Am. Fam. Phys.*, 2009, 80:157-162.
19. Karadaş, C. and Kara, D. Chemometric approach to evaluate trace metal concentrations in some spices and herbs. *Food Chem.*, 2012, 130:196-202.
20. Britton, R. S. (1996) Metal- induced hepatotoxicity. *Seminars in Liver Disease*, 1996, 6:3-12.
21. Nishimori, H., Kondoh, M., Isoda, K., Tsunoda, S., Tsutsumi, Y. and Yagi, K. Histological analysis of 70-nm silica particles-induced chronic toxicity in mice. *Eur. J. Pharm. Biopharm.*, 2009, 72: 626-629.



22. Liu, T., Li, L., Teng, X., Huang, X., Liu, H., Chen, D., Ren, J., He, J. and Tang, F. Single and repeated dose toxicity of mesoporous hollow silica nanoparticles intravenously exposed mice. *Biomaterials*, 2011, 32:1657–1668.
23. Liu, J. Evaluation of estrogenic activity of plant extracts for the potential treatment of menopausal symptoms. *Journal of Agricultural and Food Chemistry*, 2001, 49:2472–2479.
24. Liu, J. Isolation of linoleic acid as an estrogenic compound from the fruits of *Vitex agnus-castus* L. (chaste-berry). *Phytomedicine*, 2004, 11:18–23.
25. Shah AH, Bhandari MP, Al-Harbi NO, Al-Ashban RM. Kaff-E-Maryam (*Anastatica Hierochuntica* L.): Evaluation of Gastro-Protective Activity and Toxicity in Different Experimental Models. *Biol Med*, 2014, 6: 197. doi: 10.4172/0974-8369.1000197.

